

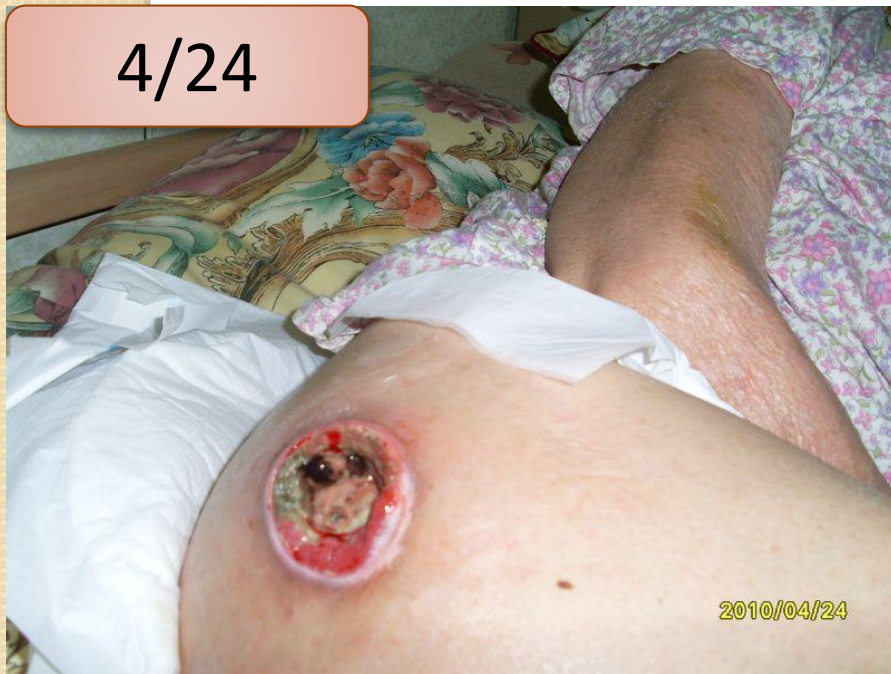

Clinical case studies on Algi-White Wound dressing

Case 1 (1/6)

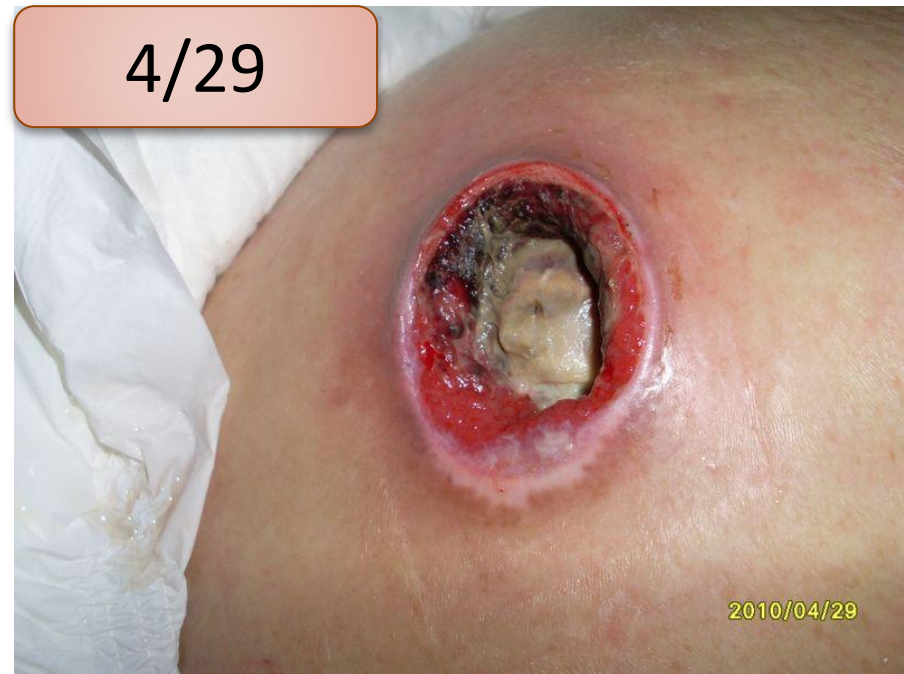

- Pressure sore (Gin-Xing nursing home)
- Female, 93 years old



4/24

Before debridement



4/29

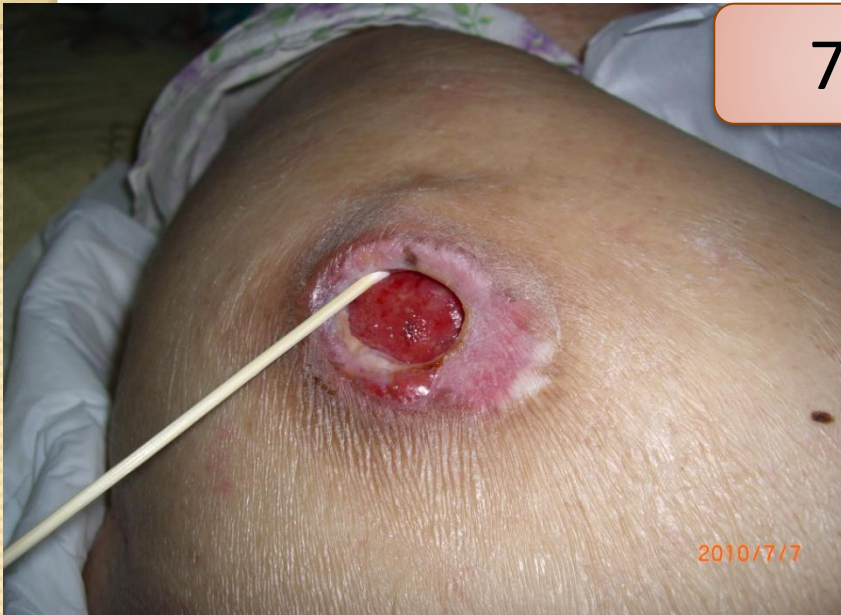Before debridement

(2/6)

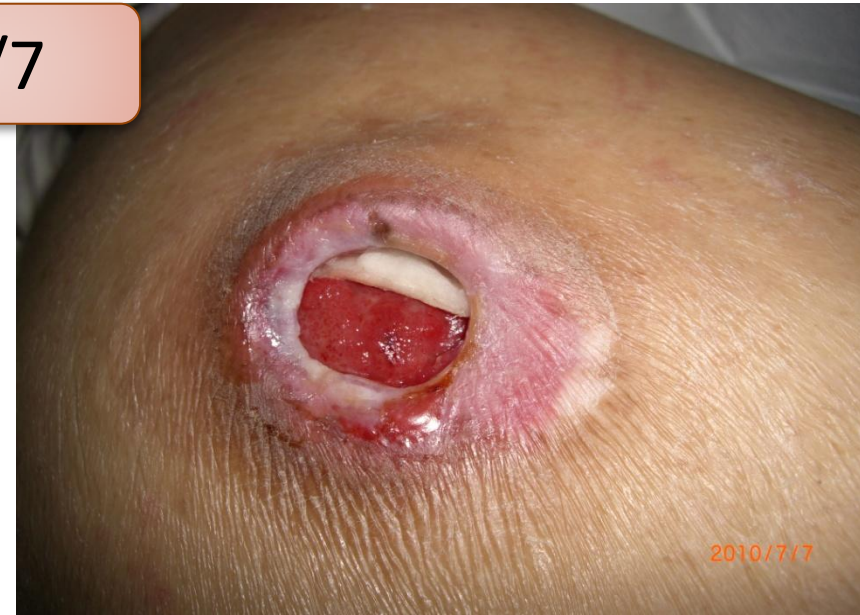

- Treatment starts.

7/7



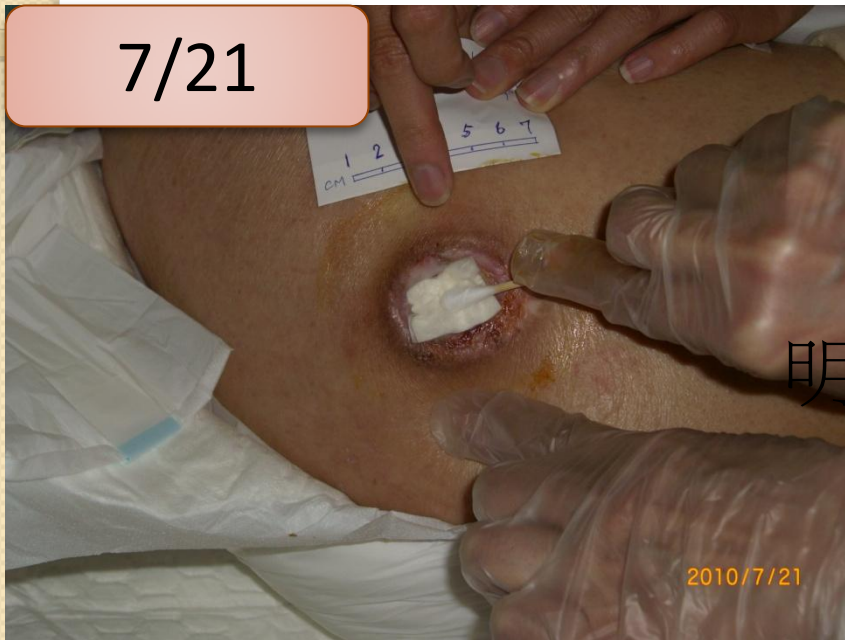Switch dressing from hydrocolloid film to Algi-White



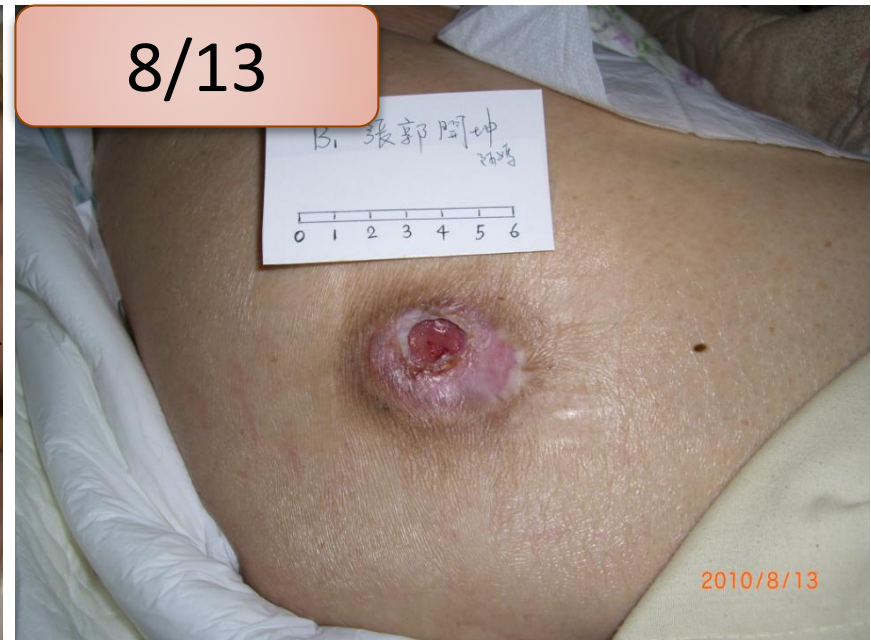Insert dressing to ensure contact with tissue and spray saline once every 8 hours to add moisture

(3/6)

- At 2, 6-week follow-up



With shrink of wound, dressing can be changed to a smaller size of Algi-White (3x3cm).



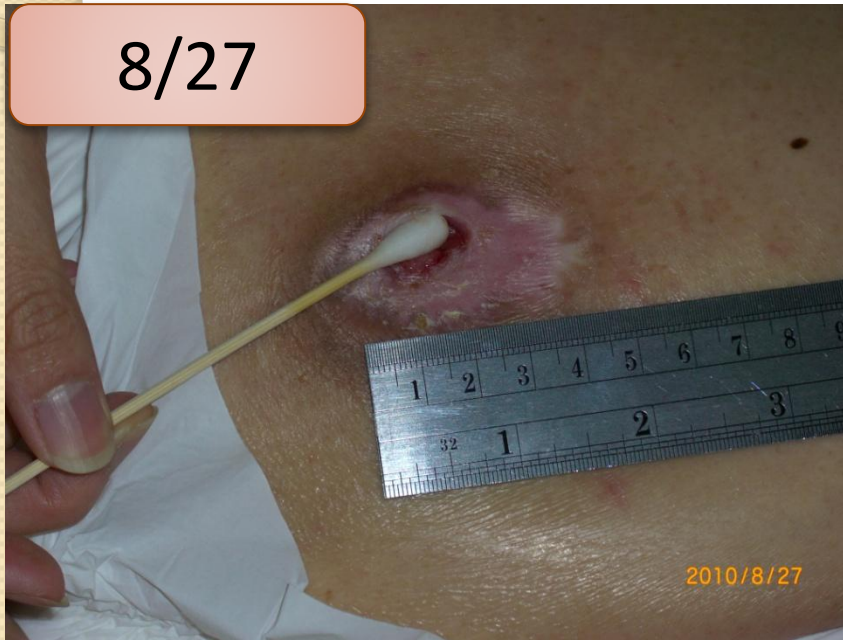After 6 weeks and 17 dressings used, wound recovery is phenomenal.

(4/6)



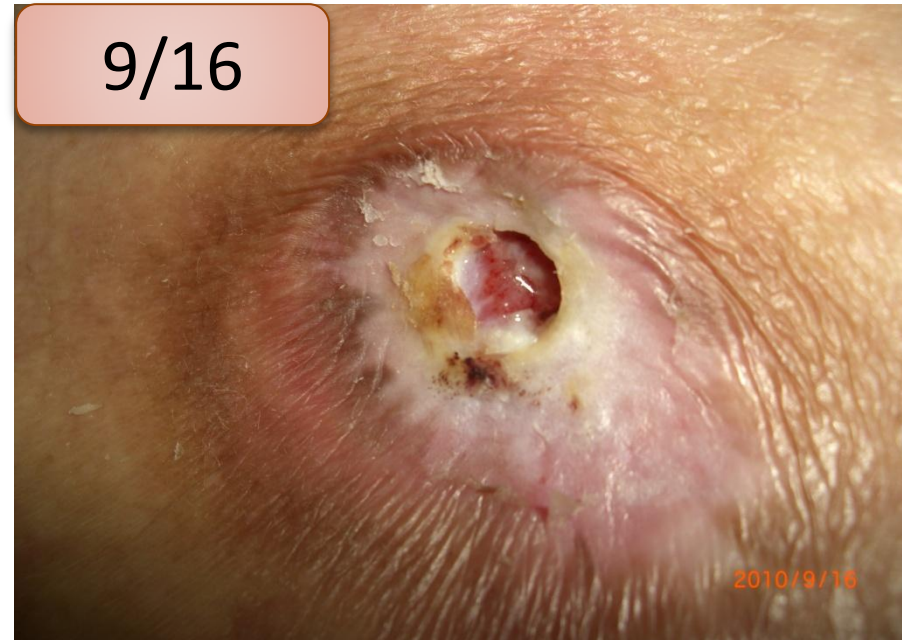- At 8, 10-week follow-up

8/27



Tissue proliferation over the wound edge is clear. The wound declines to 2.5cm in diameter.

9/16



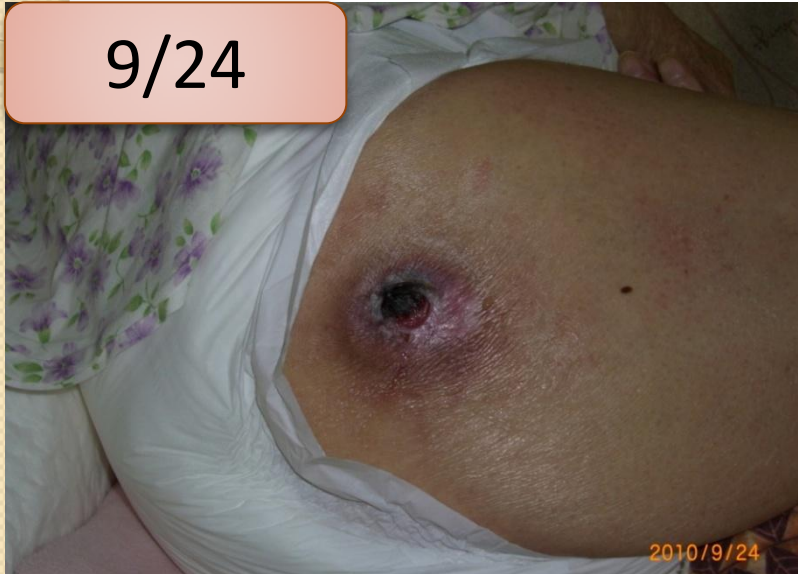Healing continues. In this photo, the thick white substance is the left-over of Algi-White.

(5/6)



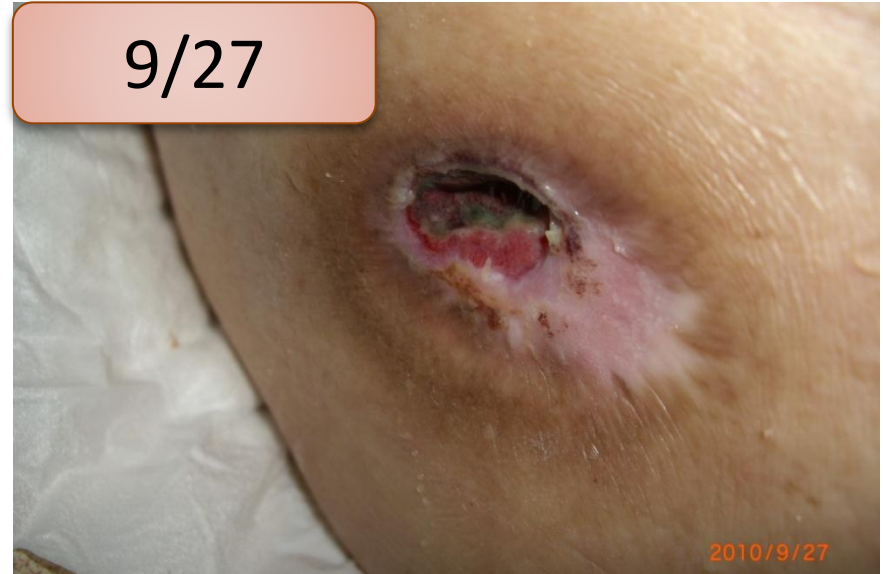- At 11-week follow-up

9/24



New nurse failed to keep Algi-White in full contact with tissue. Eschar emerged in the bottom in as short as a week .

9/27



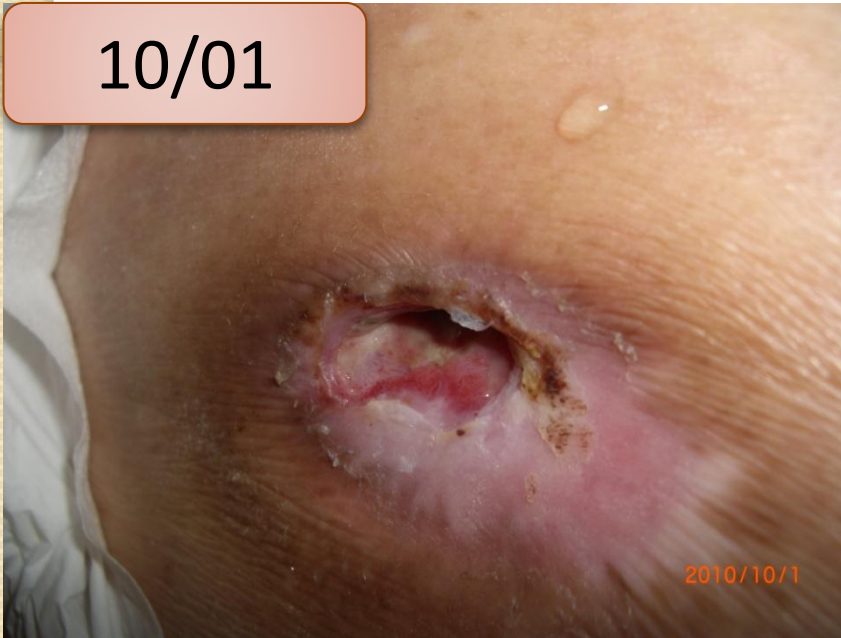Train the new nurse to follow the correct method of application. Eschar diminished in three days.

(6/6)



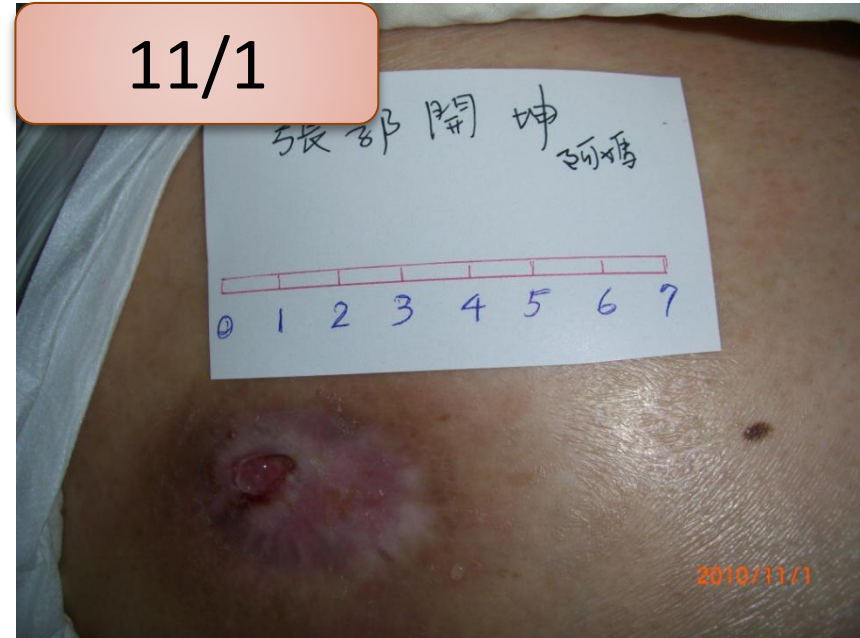- At 12, 16-week follow-up

10/01



Applied Algi-white correctly for a week, wound turned into neat and clean again.

11/1

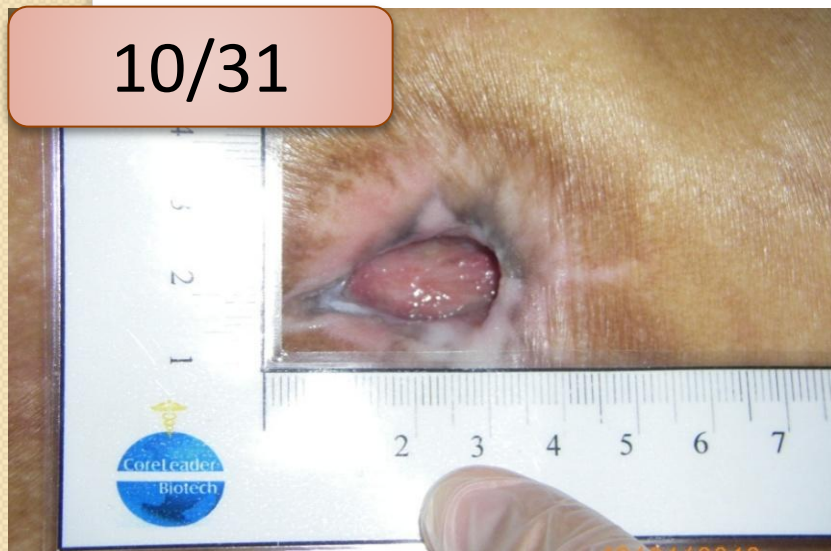


After 120 days, pressure sore is healed by 95%

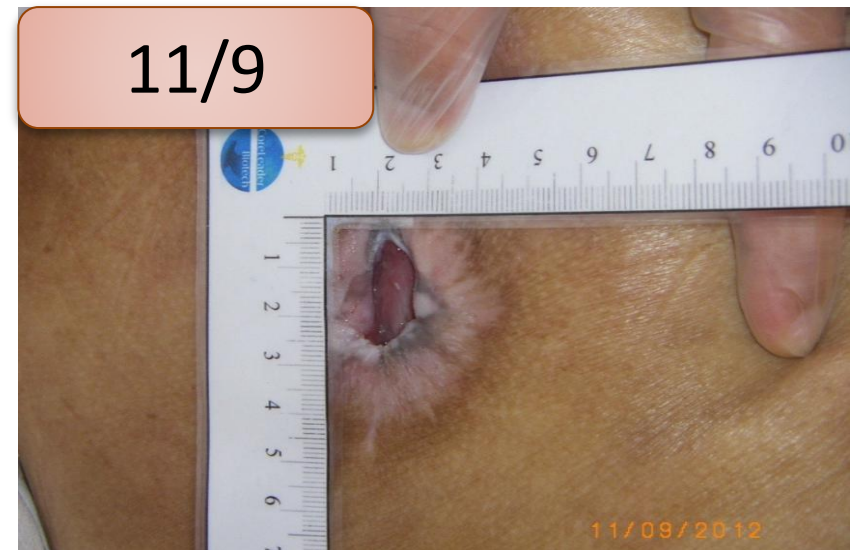Case 2 (1/2)



- Pressure sore (Chung Xing hospital)
- Male, 65 years old.



The pressure sore is 2cm in length and 1.5 cm in depth at lower back.



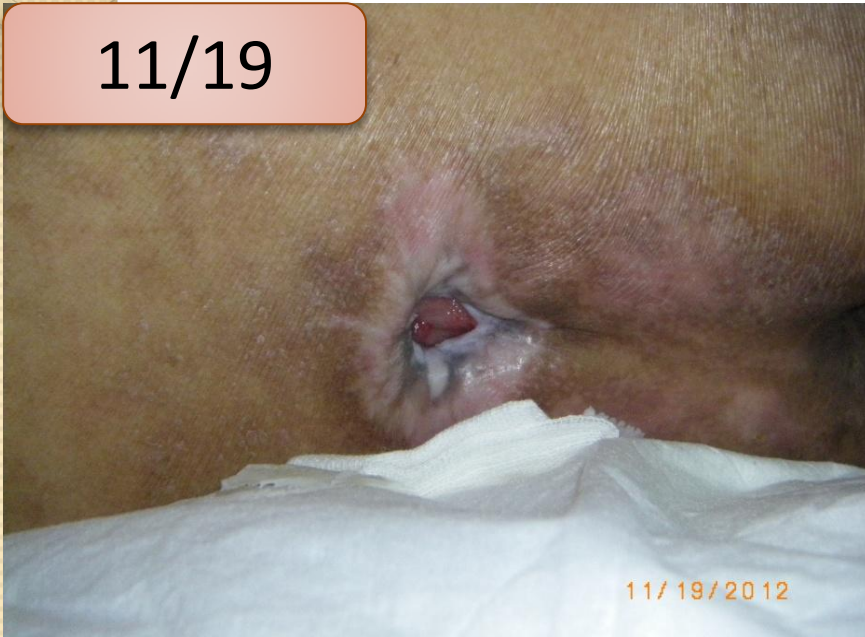After applying Algi-White for a week, the wound resumed inflammation .

(2/2)



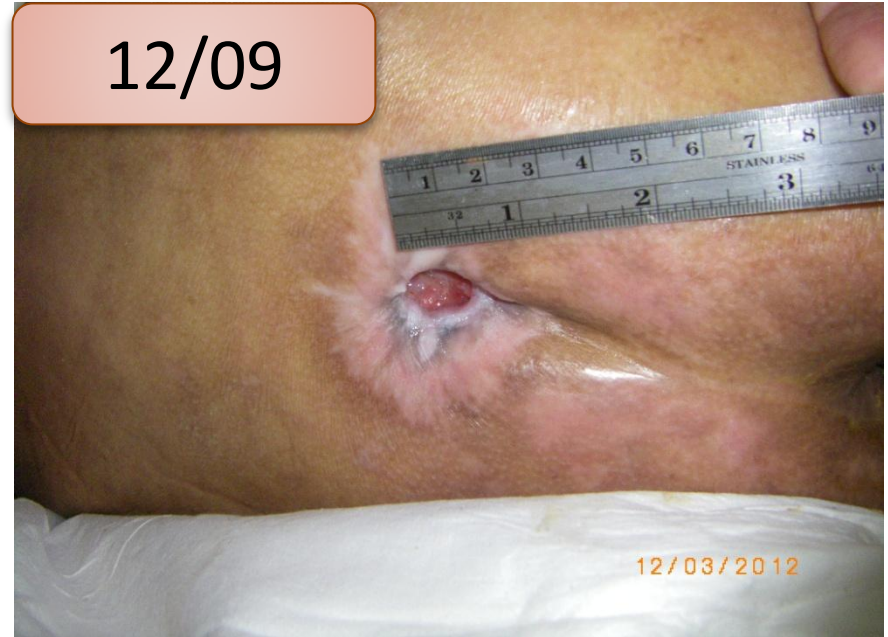- At 3, 6-week follow up

11/19



After three weeks, the wound shrunk with encouraging changes.

12/09

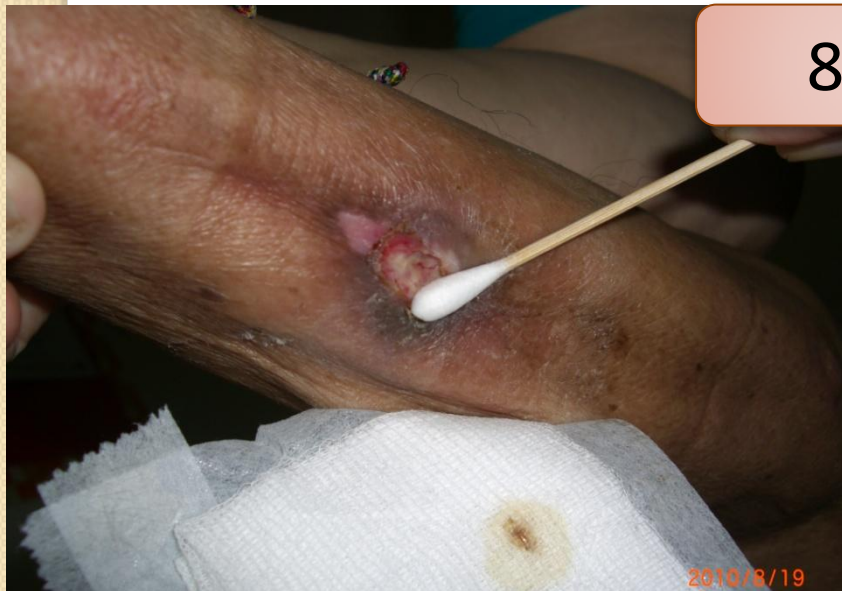

After 6 weeks, healing continues until the patient passed away.

Case 3 (1/2)

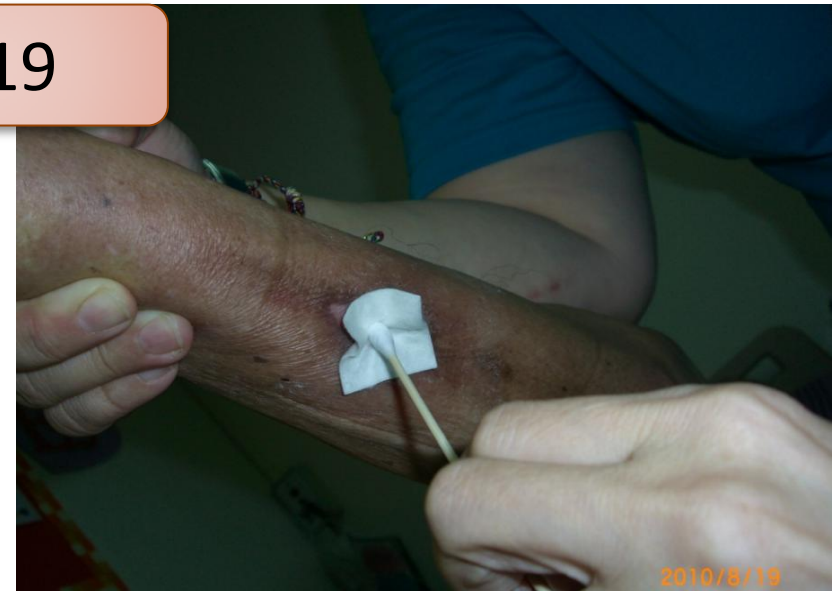

- Pressure sore, lower limb
- Male, 75 years old



8/19

The paralyzed patient develop such big sore.

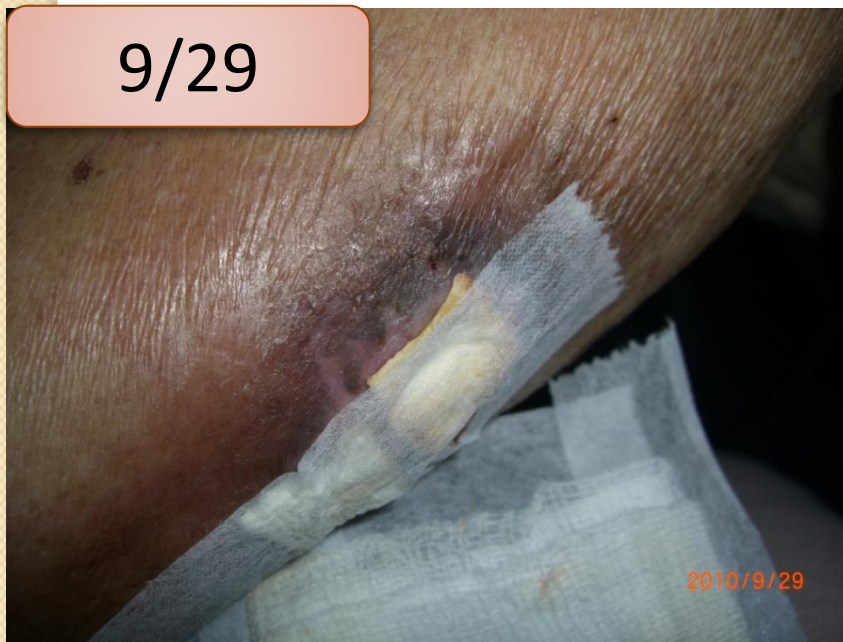

Insert Algi-White rinsed with saline thoroughly.

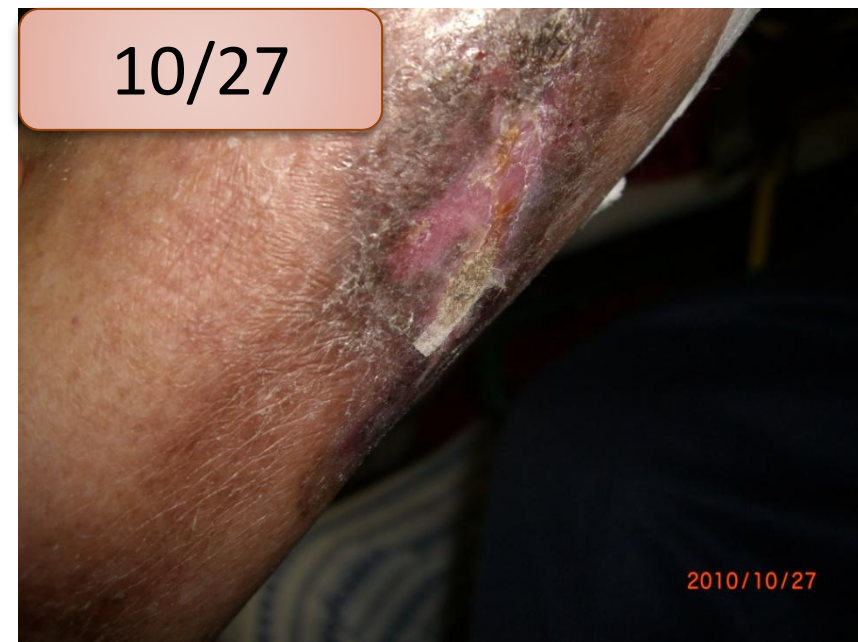(2/2)



- At 5, 9-week follow-up



Also, Algi-white was used to perform the autolysis.

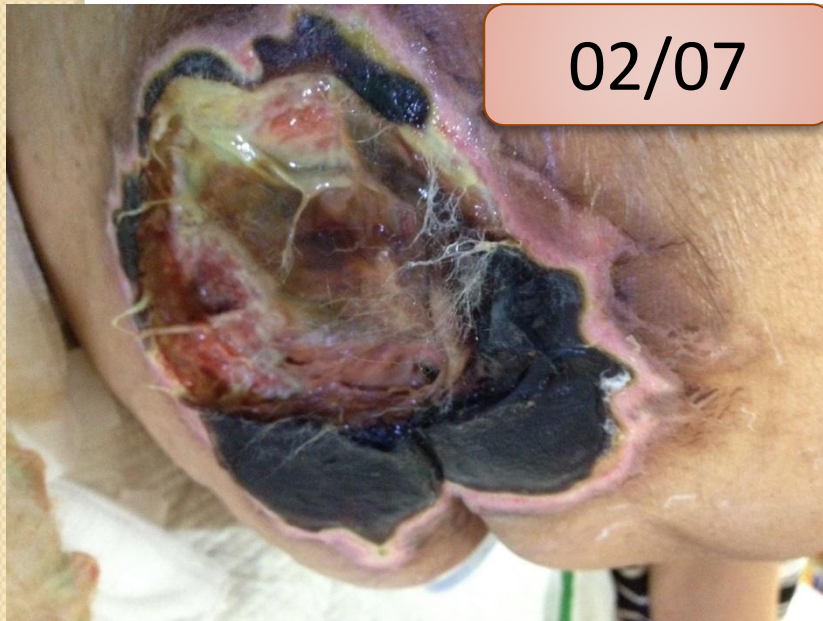

Bravo, fully healed by end Oct.

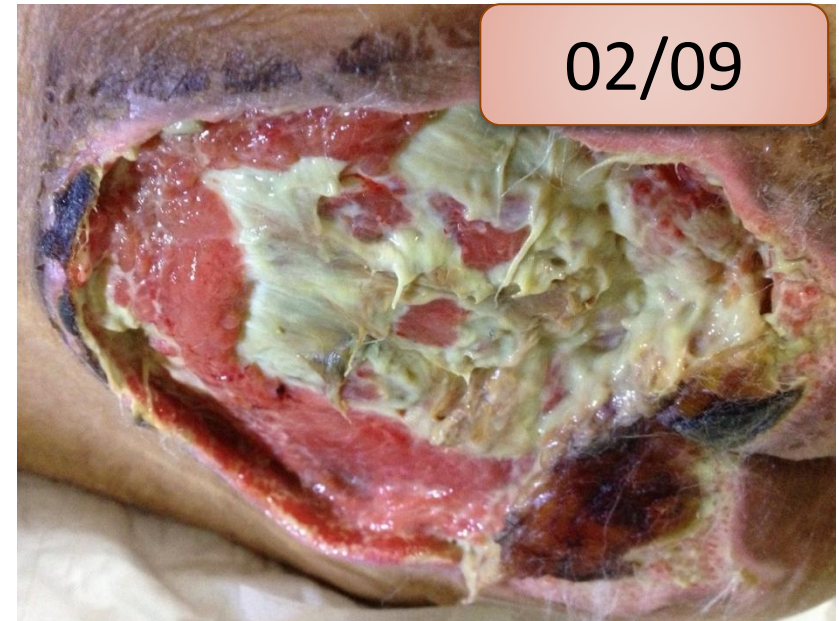
Case 4 (1/2)



- Pressure sore with multi-infections
- Female, 88 years old.



Located at the lower back was a sizable pressure sore.



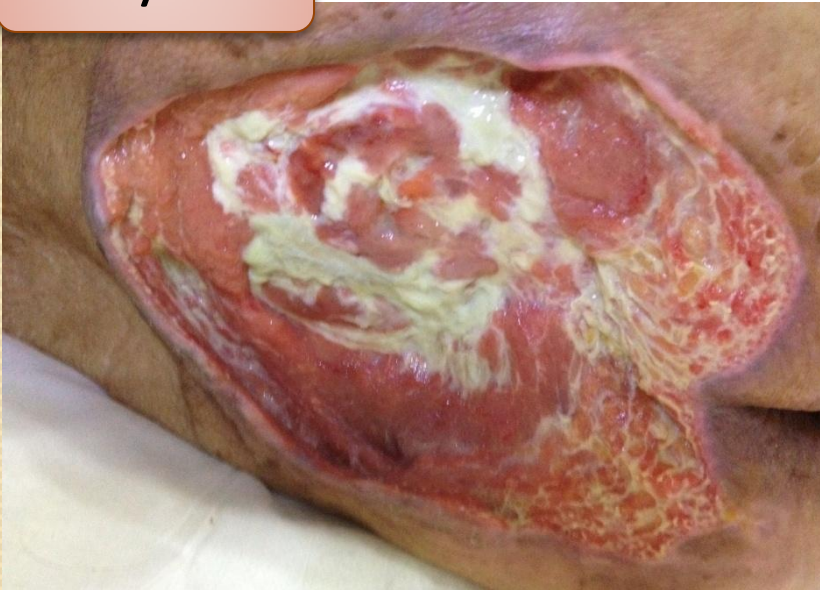After debridement, the depth of wound was revealed

(2/2)



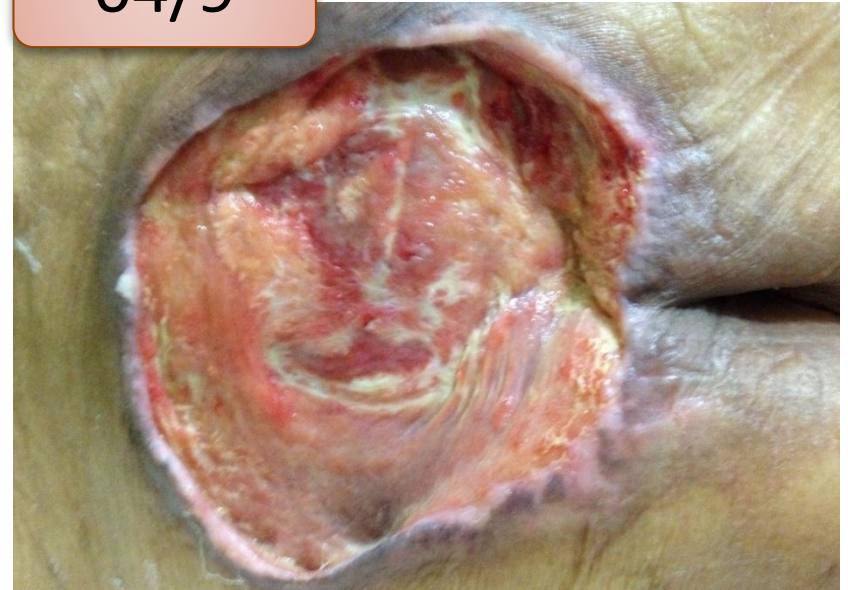- At 2, 7-week follow-up

02/25



Applied Algi-white for around 2 weeks, healing over the wound is clear.

04/9



Treated with Algi-white for 7 weeks, wound shrunk, and tissue generated with good epithelialization.